


PATIENT

Kona D'Amario

SPECIES

Feline

BREED

DSH

SEX

Female Spayed

AGE

14 years

WEIGHT

7.3lbs

INTERPRETED BY

 Maggie Machen Lamy,
 DVM DACVIM
 (Cardiology)

IMAGING PERFORMED BY

Kelly Reschny, RVT

HOSPITAL NAME

 Headon Forest
 Animal Hospital

REFERRING VET

Dr. Teminski

INVOICE

25517

DATE

7/25/22

PRESENTING CLINICAL SIGNS

History: Pre-anesthetic chest x rays revealed VHS 7.2 Heart - on VD is slanting towards the L side of chest. In lateral is leaning on the sternum. Lungs - normal age-related changes. Tracheal WNL. musculoskeletal WNL. No murmur or arrhythmia appreciated.

-Abnormal PE/Chem/CBC/UA Results: Moderate lymphocytosis, rest of values WNL. UA - 1.049, 1+ protein (due to dental dz and conc) viral - negative fecal negative. ProBNP - elevated 190.

ECHOCARDIOGRAM FINDINGS

2D, m-mode, color flow and doppler imaging is available. The left ventricular wall is normal in dimension. There is a diffusely hyperechoic endocardium consistent with age-related fibrosis. Minimal remodeling. The papillary muscles are hyperechoic. The left atrium is normal in size. The right atrium is normal in size. The right ventricle appears normal. The mitral valve is normal in structure and mobility. No MR. The tricuspid valve appears normal in structure and mobility. No TR. Blood flow through both the LVOT and RVOT are normal in velocity. No effusions. No obvious cardiac tumors.

CARDIAC CHART

FELINE CARDIAC PARAMETERS	BODY WEIGHT (kg)	HR (BPM)	IVSd (cm) <small>(Moise, Pipers)</small>	LVIDd (cm) <small>(Moise, Pipers)</small>	LVWd (cm) <small>(Moise, Pipers)</small>	FS (%)	EF (%)
NORMAL PARAMETER	-----	150-240	0.35-0.55	<2 (mean 1.5)	3.5-0.55	35-67	80-100
PATIENT	3.29	200	0.41	1.1	0.39	54	88
FELINE CARDIAC PARAMETERS	LA/AO <small>(Boon)</small>	LA/AO HEART BASE (Swe) <small>(Abbott)</small>	LA 2D short axis Base view (cm) <small>(Abbott)</small>		LVOT VEL <small>(m/s)</small>	RVOT VEL <small>(m/s)</small>	E max <small>(m/s)</small>
NORMAL	<1.5	<1.3	<1.2		<1.6	<1.3	<0.9
PATIENT	NM	1.0	1.0		0.94	0.98	NM

**Note: All measurements based upon multi-modal images and methods. An average value is reported.*
 Adapted from June Boon, Veterinary Echocardiography, 1998
 Abbott J & MacLean H JVIM 2006;20: 111-119, Moise et al. Am J Vet Res 47:1476, 1986. Pipers et al. Am J Vet Res 40:882, 1979.

INTERPRETATION OF THE FINDINGS & FURTHER RECOMMENDATIONS

Overtly normal cardiac structure and function. The LV wall thickness is normal, and there is no evidence of elevated left atrial pressure or underlying pathology at this time. There is mild remodeling and fibrosis of the left ventricular wall, which is considered likely a normal age-related finding. Given these findings, no medications are indicated.

No obvious structural cause for BNP elevation is seen here. A flaw of the BNP test is false positives, which may be the case; however, alternative causes for elevation should be considered, including decreased renal clearance, hypertension, etc. If no obvious cause is identified, reassessing this patient in 6-12 months is recommended to ensure early disease was not missed.



PATIENT

Kona D'Amario

SPECIES

Feline

BREED

DSH

SEX

Female Spayed

AGE

14 years

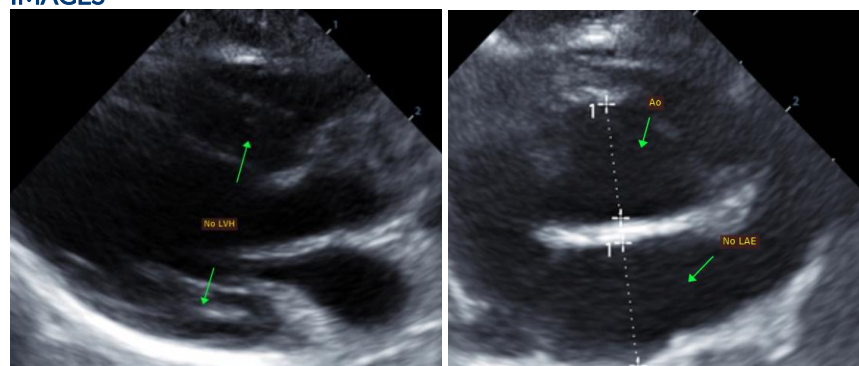
WEIGHT

7.3lbs

Anesthetic risk is considered mild. With remodeling and diastolic stiffening, there is an elevated risk for fluid overload in this patient and judicious IV fluid use is recommended. Heart rate stimulating drugs such as atropine, glycopyrrolate or ketamine should be avoided unless medically necessary. Risk for complication with steroid use typically follows LA dilation, which in this case is low. That being said, any cat can experience unexpected signs of intolerance and monitoring of RR/RE is advised particularly in the initiation phase.

Recommend recheck echocardiogram in 1 year to assess for any progressive issues.

IMAGES



The information and recommendations provided are based on the images presented by the referring veterinarian. No evaluation can be communicated regarding pathology that was not visible in the image/video clips provided.

Thank you for this referral. This report was generated using transcription software, and minor dictation errors may be present. If the clinical or image interpretation does not parallel your findings or if I can be of any further assistance, please contact me.

INTERPRETED BY

Maggie Machen Lamy,
DVM DACVIM
(Cardiology)

Maggie Machen Lamy, DVM
Diplomate of the American College of Veterinary Internal Medicine (Cardiology)
info@sonopath.com

IMAGING PERFORMED BY

Kelly Reschny, RVT

HOSPITAL NAME

Headon Forest
Animal Hospital

REFERRING VET

Dr. Teminski

INVOICE

25517

DATE

7/25/22